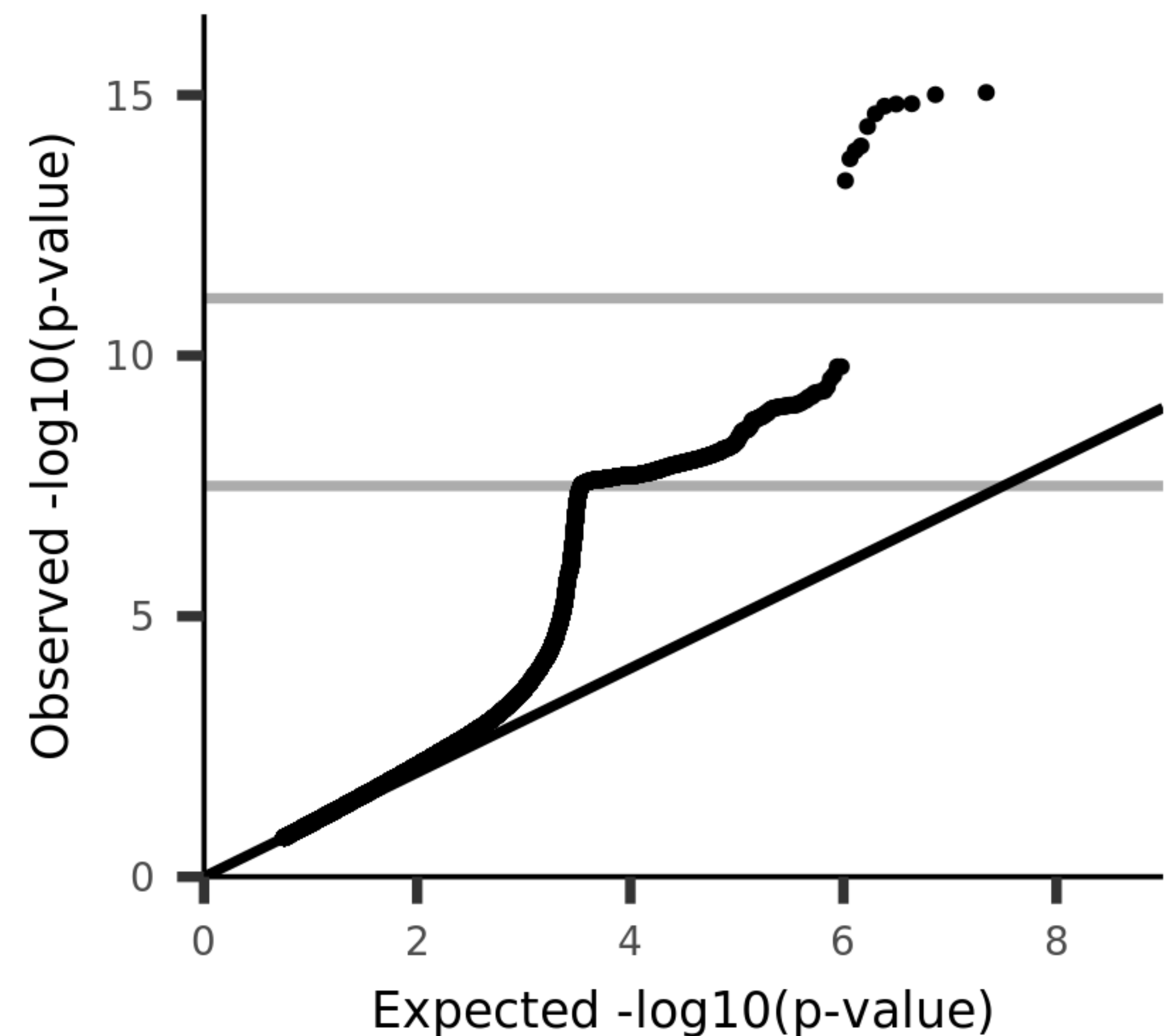
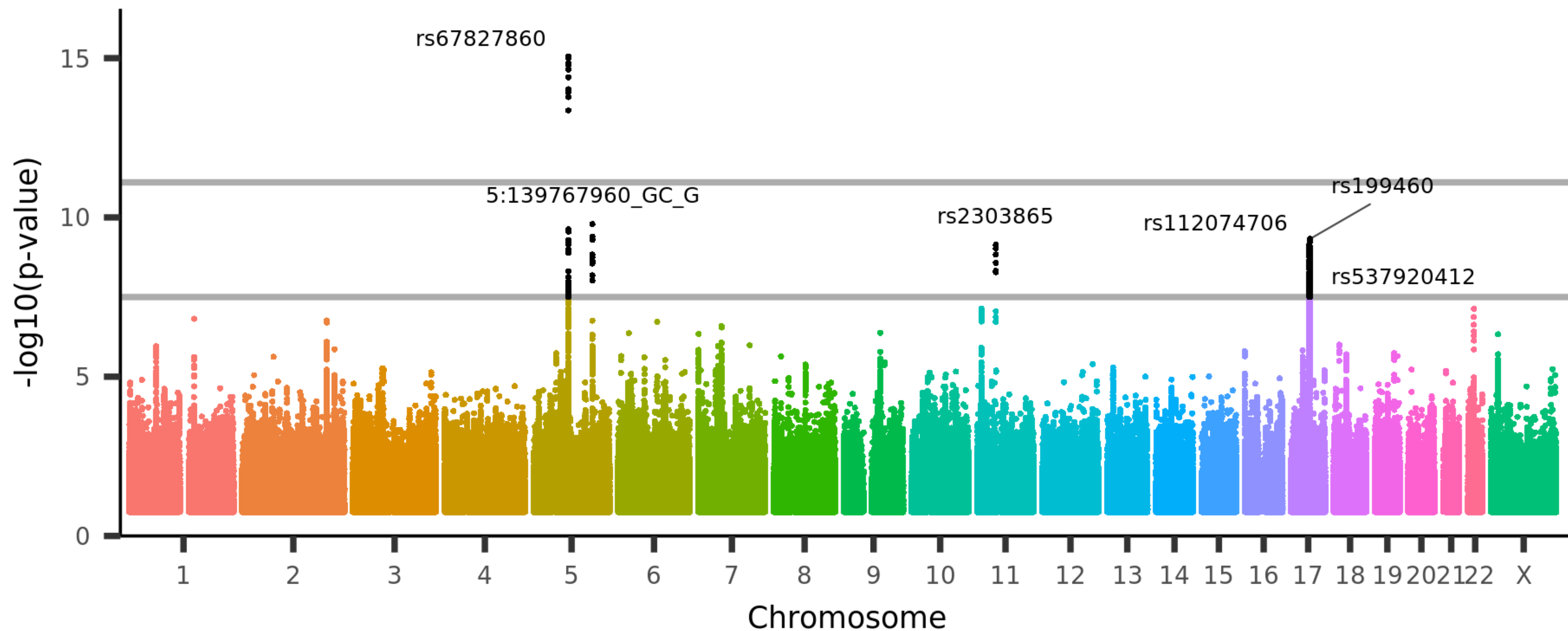


V1620



UKB_ID 25122, (IDP_dMRI_TBSS_MD_Posterior_limb_of_internal_capsule_R)
Mean MD (mean diffusivity) in posterior limb of internal capsule (right) on FA (fractional anisotropy) skeleton (from dMRI data)