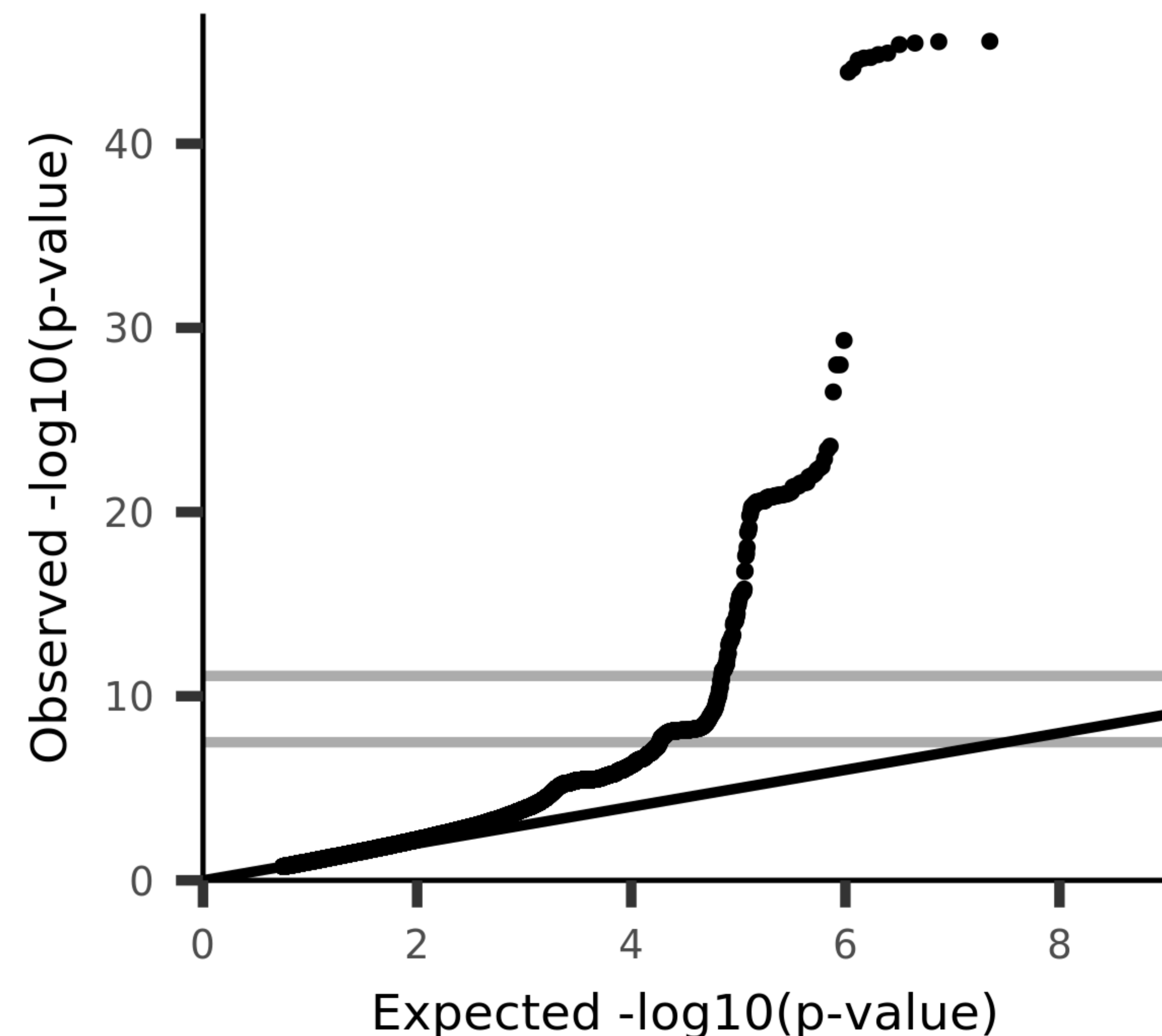
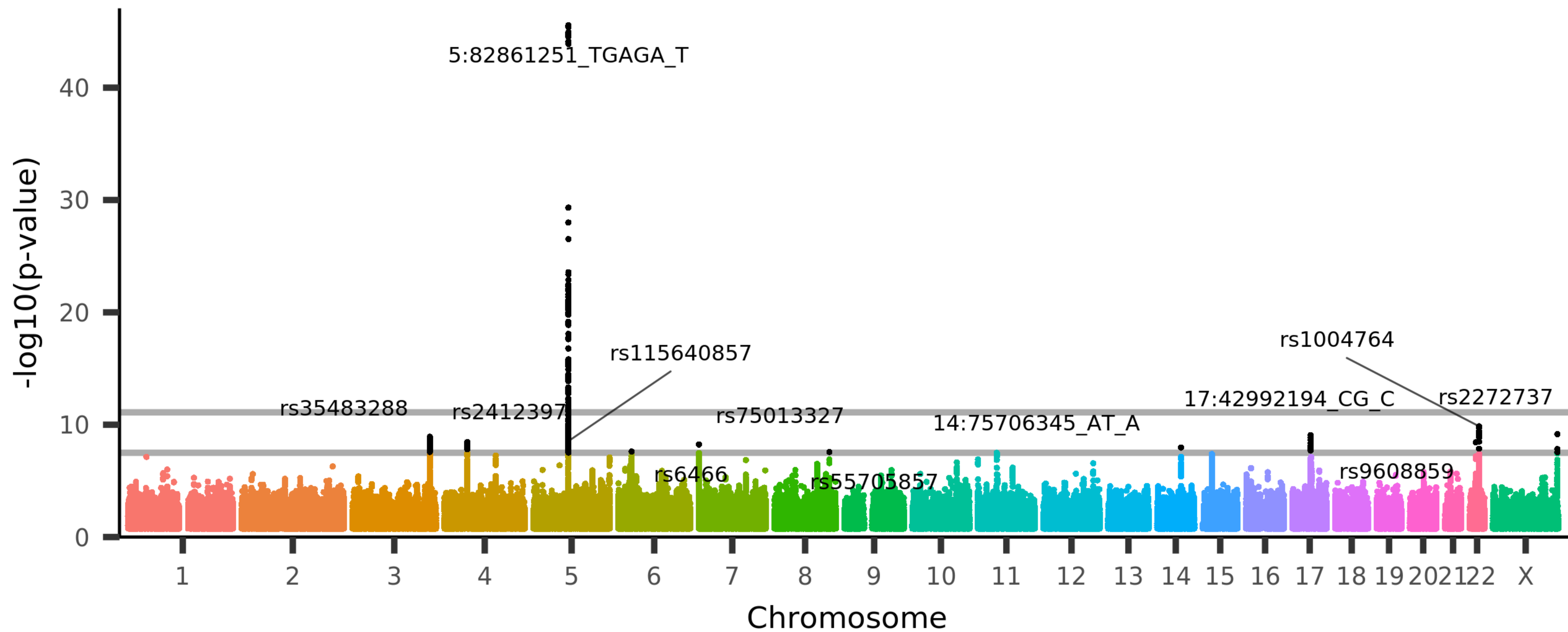


V1887



UKB\_ID 25635, (IDP\_dMRI\_ProbtrackX\_L3\_ifo\_I)  
Weighted-mean L3 in tract left inferior fronto-occipital fasciculus (from dMRI data)